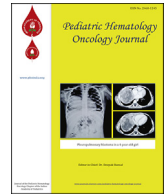



Contents lists available at ScienceDirect

Pediatric Hematology Oncology Journal

journal homepage: www.journals.elsevier.com/pediatric-hematology-oncology-journal



Isosexual precocious pseudopuberty during mitotane treatment in a child with adrenocortical carcinoma: A case report

Maria Riedmeier ^a, Sonir Antonini ^b, Clemens Benoit ^a, Cheri L. Deal ^c, Fassnacht Martin ^{b, d}, Bonald C. Figueiredo ^e, Elmas Nazli Gonc ^f, Christoph Härtel ^{a, g}, Jan Idkowiak ^{h, i, j}, Max Kurlbaum ^d, Ronald de Krijger ^{k, l}, Raul C. Ribeiro ^m, Jaydira del Rivero ⁿ, Paul-Gerhardt Schlegel ^{a, g}, Lester D.R. Thompson ^o, Bilgehan Yalcin ^p, Verena Wiegering ^{a, g, *}

^a University Hospital Würzburg, Department of Pediatrics, Division of Pediatric Hematology, Oncology and Stem Cell Transplantation, University of Würzburg, Josef-Schneiderstr. 2, 97080, Würzburg, Germany

^b Department of Pediatrics, Ribeirao Preto Medical School, University of Sao Paulo, Brazil

^c Research Center, CHU Sainte Justine and the University of Montreal, Canada

^d Department of Medicine, Division of Endocrinology and Diabetes, University Hospital, University of Würzburg, Oberduerrbacherstr. 6, 97080, Würzburg, Germany

^e Pelé Pequeno Príncipe Research Institute and Pequeno Príncipe Faculty, Silva Jardim Avenue, Água Verde, Curitiba, PR, 80.250-200, Brazil

^f Department of Pediatric Endocrinology, Hacettepe University, Faculty of Medicine, 06100, Ankara, Turkey

^g Comprehensive Cancer Centre Mainfranken, University of Würzburg Medical Centre, Josef-Schneiderstr. 2, 97080, Würzburg, Germany

^h Institute of Metabolism and Systems Research, College of Medical and Dental Sciences, University of Birmingham, United Kingdom

ⁱ Department of Endocrinology and Diabetes, Birmingham Women's and Children's NHS Foundation Trust, Birmingham, United Kingdom

^j Centre of Endocrinology, Diabetes and Metabolism, Birmingham Health Partners, University of Birmingham, Birmingham, United Kingdom

^k Princess Maxima Center for Pediatric Oncology, Heidelberglaan 25, 3584 CS, Utrecht, the Netherlands

^l Department of Pathology, University Medical Center Utrecht, Heidelberglaan 100, 3584 CX, Utrecht, the Netherlands

^m Departments of Oncology and Global Pediatric Medicine, St. Jude Children's Research Hospital, Memphis, TN, USA

ⁿ Developmental Therapeutics Branch, Rare Tumor Initiative, Center for Cancer Research, National Cancer Institute, Bethesda, MD, USA

^o Head and Neck Pathology Consultations, Woodland Hills, CA, 91364, USA

^p Department of Pediatric Oncology, Hacettepe University Faculty of Medicine, 06100, Ankara, Turkey

ARTICLE INFO

Article history:

Received 15 September 2023

Received in revised form

5 March 2024

Accepted 10 March 2024

Available online 11 March 2024

Keywords:

Pediatric adrenocortical cancer
Pediatric adrenocortical carcinoma
Pediatric adrenocortical tumor
Precocious puberty
Mitotane therapy
Treatment

ABSTRACT

Background: Mitotane is employed as adjuvant therapy in managing adrenocortical carcinoma in pediatric patients. While various adverse effects, such as estrogen-like manifestations, are well-documented in adults, there is limited knowledge regarding pediatric-specific toxicity. This report details an uncommon case of isosexual precocious pseudopuberty induced during childhood due to the estrogen-like effects of mitotane.

Case report: A 2.8-year-old female diagnosed with adrenocortical carcinoma (pT4 pN0 M0) underwent adjuvant treatment with mitotane and cytotoxic chemotherapy following incomplete resection (tumor stage III). Approximately eight months into mitotane treatment, she exhibited signs of puberty (Tanner stage 2), including progressive breast development, uterine enlargement, vaginal discharge, and an advancement of bone age by nearly two years. Gonadotrophin-dependent puberty and endogenous estrogen production were ruled out. The precocious pseudopuberty was attributed to previously reported estrogen-like effects of mitotane therapy. Subsequent administration of the aromatase inhibitor anastrozole in combination with mitotane led to a reduction in clinical signs of puberty.

Conclusion: Monitoring for estrogen-like effects of mitotane is crucial, particularly in pre-pubertal children, to avert potentially irreversible changes associated with precocious pseudopuberty.

* Corresponding author. Department of Pediatrics Division of Hematology, Oncology and Stem cell Transplantation, University Hospital Würzburg, Josef-Schneiderstr. 2, 97080, Würzburg, Germany.

E-mail address: Wiegering_v@ukw.de (V. Wiegering).

Peer review under responsibility of Pediatric Hematology Oncology Chapter of Indian Academy of Pediatrics.

Aromatase inhibitors may serve as a prompt therapeutic option, enabling the continuation of mitotane treatment.

© 2024 Publishing Services by Elsevier B.V. on behalf of Pediatric Hematology Oncology Chapter of Indian Academy of Pediatrics. This is an open access article under the CC BY-NC-ND license (<http://creativecommons.org/licenses/by-nc-nd/4.0/>).

1. Introduction

Pediatric adrenocortical carcinoma (pACC) is an exceedingly rare, neoplasm, predominantly (>90%) functioning, and it carries a grim prognosis in advanced stages [1]. The pathogenesis of pACC is linked to TP53-related cancer syndromes, including Li-Fraumeni syndrome (LFS), attributable to a specific inherited germline mutation at codon 337 in the TP53 suppressor gene [2–4]. The therapeutic approach to managing ACC includes surgery [5,6], chemotherapy, and mitotane a synthetic derivative of the insecticide dichlorodiphenyltrichloroethane [DDT] - are pivotal components of the therapeutic strategy for advanced pACC [7,8]. Mitotane, operating as an antineoplastic agent with specific adrenocortical activity, induces necrosis of cells in the zona glomerulosa and zona reticularis, subsequently inhibiting steroid hormone production [7,8]. This inhibition of the adrenal cortex by mitotane results in adrenal insufficiency, often necessitating concurrent glucocorticoid replacement therapy employing hydrocortisone/cortisone acetate, particularly when ongoing cortisol excess resulting from tumor overproduction is ruled out [9,10]. The toxicities associated with mitotane in pediatric patients exhibit a diverse range, encompassing gastrointestinal, neurological, endocrinologic, and hematological toxicity [9,11]. Notably, adverse effects affecting the central nervous system are more prevalent and may pose life-threatening risks. Nevertheless, the majority of the adverse effects, including severe neurotoxicity, tend to be reversible upon discontinuation of mitotane. Concerning endocrinological adverse effects of mitotane, the estrogen-like adverse effects, attributed to its agonistic activity on the estrogen receptor- α [8], are well-documented in adults. The current report emphasizes a rare case of isosexual precocious pseudopuberty in childhood, precipitated by the estrogen-like actions of mitotane.

2. Case report

A 2.8-year-old female initially presented with abdominal pain for two weeks, accompanied by signs of virilization, including adrenarche and clitoral hypertrophy, over approximately two months. MRI imaging revealed an encapsulated, solid tumor in the right adrenal cortex with partially hemorrhagic necrotic segments (Fig. 1). Endocrine work-up confirmed increased androgen production, as detailed in Table 1. After the diagnosis of functioning adrenocortical neoplasm, a right adrenalectomy and tumor resection were performed, resulting in an incomplete (R1) resection. Histological examination identified the tumor as an 11 x 8 x 5cm, 330 g adrenocortical tumor, displaying features of epithelioid neoplasia with atypical adrenocortical cells exhibiting a solid growth pattern. Localized involvement of the inferior vena cava (R1 resection) was observed, accompanied by increased mitotic activity (>5 mitoses/5 mm²; Ki-67 proliferation index 15%) and tumor comedonecrosis. Based on these findings, a definitive diagnosis of an adrenocortical carcinoma was established, with a Wieneke score [12] of five considering size, mitoses, tumor necrosis, local venous invasion, and invasion into vena cava. The tumor was staged as stage III (pT4 pN0 M0). Genetic analysis ruled out the presence of germline pathogenic variants in TP53.

Following the surgical procedure, adjuvant chemotherapy was administered in accordance with the German protocol outlined by the Gesellschaft für pädiatrische Onkologie und Hämatologie – maligne endocrine Tumore im Kindes- und Jugendalter (GPOH-MET 97) [13]. The chemotherapy regimen consisted of four cycles with vincristine, ifosfamide, and adriamycin, in alteration with four blocks with carboplatin and etoposide. Additionally, mitotane was prescribed for two years due to the high-risk tumor profile, which included incomplete resection, tumor volume, and the Ki67 proliferation index of $\geq 15\%$. The maintenance dose of mitotane was approximately 65 mg/kg/day, regularly adjusted to maintain a therapeutic level between 14 and 20 mg/L.

Following the initial surgical intervention, serum androgen levels and clinical manifestations of androgen excess returned to normal levels within 6 weeks postoperatively. Given the androgen production of the tumor, a slightly accelerated bone age, equivalent to 4.1 years in a 2.9-year-old girl (weight z -0.44, height z -0.04, BMI z -0.62), was observed prior to the initiation of chemotherapy. The chemotherapy course was well-tolerated without significant complications and was completed after 8 cycles (22 weeks) as per the planned schedule. Subsequent to the final chemotherapy block, abdominal magnetic resonance imaging (MRI) revealed a favorable tumor response with no evidence of residual tumor or relapse (Fig. 1).

Approximately eight months following the initiation of mitotane therapy and about eight weeks post-completion of cytotoxic chemotherapy, the patient exhibited breast development (Tanner stage I) and uterine enlargement (volume of 30 ml, endometrium thickness 3.3mm) as detected on pelvic MRI. The documented mitotane level was approximately 14 mg/L. The patient presented with mild abdominal discomfort, grade 1–2 ataxia, adrenal insufficiency, and central hypothyroidism as additional adverse effects. Consequently, substitution with hydrocortisone, fludrocortisone, and L-thyroxine was necessitated. Continued mitotane therapy over the subsequent year resulted in progressive signs of puberty,

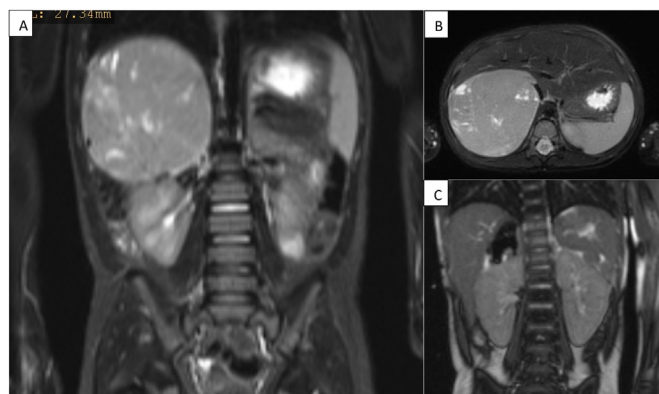


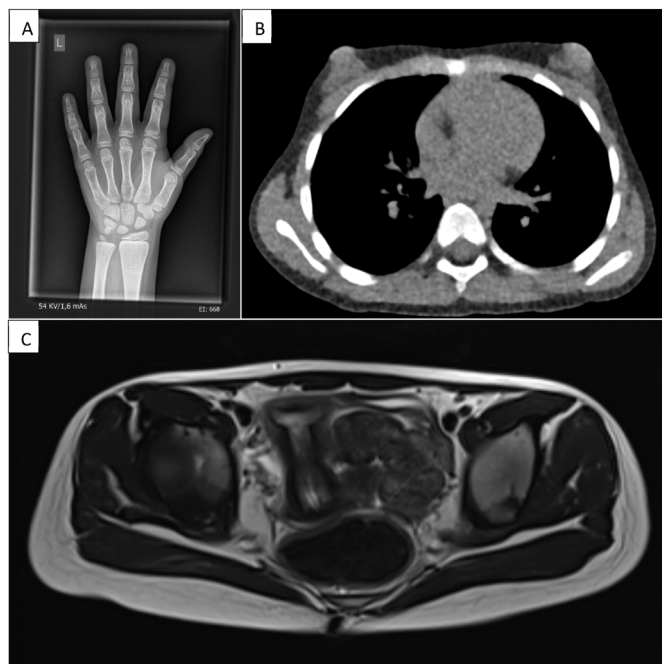
Fig. 1. Radiological imaging of the tumor at the time of presentation and two months after tumor resection

A (coronal plane) and B (axial plane): MRI conducted at the time of diagnosis prior to surgery reveals an encapsulated, solid tumor located in the right adrenal cortex, characterized by partially hemorrhagic necrotic segments. C: Post-surgical MRI illustrates the absence of macroscopic tumor remnants in coronal plane..

Table 1

The outcomes of endocrinological assessments, encompassing laboratory examinations, carpogram results, and SMR staging at distinct time points.

Endocrinological assessment	At diagnosis (before resection)	18 months after starting mitotane	6 months after starting anastrozole	Reference values
Laboratory examinations				
DHEA-S (μmol/l)	3041	0.5	0.005	0.01–0.5
Testosterone (nmol/l)	579	0	0	0.1–0.4
Androstenedione (nmol/l)	1540	0.5	<0.07	0.05–0.4
Estradiol E2 (pmol/L)		18.4	18.4	<37
ACTH (pmol/l)		14.1	0.3	0–63.3
LH (IU/L)		0.85		0.23–1.85
FSH (IU/L)		0.3		0.19–3.28
Carpogram				
Bone age (years)	4.1	5.8	5.8	
Chronological age (years)	2.8	4.2	4.8	
Height age (years)	2.8	4.6	4.7	
SMR staging (Tanner)	0	2	2	

**Fig. 2.** Radiological imaging taken 18 months after the commencement of mitotane therapy

A: Carpogram of the left hand reveals an accelerated bone age equivalent to 6.8 years in a 5.1-year-old girl. B: Low-dose CT thorax exhibits additional breast growth at Tanner stage 2. C: Pelvic MRI indicates uterine enlargement with an uterine volume of 38 ml and an endometrial thickness of 5.8 mm.

characterized by further breast growth (Tanner stage 2) and increased uterine dimensions (volume of 38 ml, endometrial thickness 5.8 mm), alongside the onset of vaginal discharge (Fig. 2). Following the exclusion of relapse through MRI imaging and laboratory assessments, an extended endocrinological evaluation of the 4.2-year-old girl (weight z -1.93 , height z -1.09 , BMI z -1.74) revealed an accelerated bone age of 5.8 years and suppressed gonadotropins. A normal GnRH stimulation test ruled out central puberty (Table 1). The diagnosis of precocious pseudopuberty was established, presumably attributed to the previously reported estrogen-like effects of mitotane [8].

Given the high risk for recurrence (stage III ACC, incomplete resection), the continuation of mitotane therapy underwent meticulous consideration. Following consultations with numerous national and international experts, a therapeutic strategy involving an aromatase inhibitor (anastrozole 1 mg/day) was introduced. No further modification of the mitotane dosage was implemented, as

therapeutic blood levels had already been attained. The combination of anastrozole and mitotane was well tolerated. Throughout the clinical course, only a singular instance of menstrual-type bleeding occurred shortly after the initiation of anastrozole. Subsequently, the endometrial thickness decreased by half approximately three weeks into anastrozole therapy, accompanied by a gradual reduction in uterine volume (uterine volume 32.9 ml, endometrium thickness 3.4 mm, weight z -1.48 , height z -1.64 , BMI z -0.59). The aforementioned trend has persisted for six months. During this period, breast development ceased, and the progression of puberty was effectively halted, with no significant adverse effects and no further acceleration in bone growth (Table 1). Neurological adverse effects, such as mild ataxia, concentration disorders, and lack of emotional detachment, remained unchanged under the combination therapy (grade 1–2). The therapy duration for both mitotane and anastrozole adhered to a 24-month regimen in alignment with the European guidelines applicable to adult patients [9]. Regular imaging and laboratory assessments indicated that the patient is currently in complete remission subsequent to the completion of the treatment.

3. Discussion

Given the rarity of pediatric ACC, there exists a scarcity of robust evidence pertaining to the indications, treatment modalities, and management of adverse effects of mitotane treatment specific to this age group. The Children's Oncology Group (COG) proposes the utilization of a combination regimen comprising cisplatin, doxorubicin, etoposide, and mitotane exclusively for pACC patients in advanced tumor stages (\geq stage 3) [6]. The optimal duration of treatment for pediatric ACC cases is debatable. The COG recommends a duration of 8 months for stage III patients, citing excellent 5-year overall survival exceeding 90% when combined with surgery, radical lymph node resection, and chemotherapy [6]. In contrast, the European EXPeRT/PARTNER group suggests that a 2-year treatment duration best addresses the peak period of relapse risk [14]. Kühlen et al. previously demonstrated that a mitotane treatment of less than 9 months significantly impacts overall survival negatively [15]. In light of these conflicting findings, the decision for a 24-month treatment duration for the female patient of the case was based on the adult paradigm, which proposes a 24-month duration of mitotane treatment for high-risk patients [9]. Given the contentious and little evidence on mitotane treatment duration in pediatric patients, it is imperative to conduct international randomized studies to accumulate more pediatric-specific data and establish the optimal duration of mitotane therapy.

While the adverse effects of mitotane in adults are well-documented, with established guidelines for managing adult ACC

and detailed recommendations on mitotane usage published [9,16–20], the specific information and guidelines for pediatric populations are notably lacking. Our case highlights a rare but clinically significant estrogen-like adverse effect observed in prepubertal children undergoing mitotane therapy, namely precocious pseudopuberty. Given the absence of treatment recommendations tailored to this particular scenario, our presented case vignette, which illustrates a successful treatment outcome, may serve as a valuable resource for other patients and treating physicians encountering similar situations where limited experience exists in addressing such adverse effects in the pediatric population.

The induction of pseudopuberty and the therapeutic efficacy observed with the use of the aromatase inhibitor could potentially be attributed to the estrogen-like effect of mitotane. This effect may result in localized supraphysiological estrogen levels, specifically within breast and uterine tissues, rather than in the systemic circulation. One plausible explanation for this estrogen-like effect of mitotane is forming a chemical bond between the estrogen receptor- α (ER- α) and dichlorodiphenyldichloroethane (DDD) derivatives of mitotane. This interaction, as reported by Rossini et al. [8], leads to the activation of the estrogen receptor, contributing to the observed effects on breast and uterine tissues.

Ultimately, the consequences of such adverse effects necessitate an individualized risk-benefit analysis. As illustrated in this present case, co-administration of aromatase inhibitors emerges as a potent strategy to effectively mitigate these adverse effects, supporting the pathogenetic hypothesis of the estrogen-like effect of mitotane. It is crucial to note that aromatase inhibitors are not officially approved for this indication in the pediatric age group. While theoretical considerations support the efficacy of aromatase inhibitors, careful consideration must be given to the potential adverse effects of mitotane, especially when employed concomitantly with other chemotherapeutic agents.

In conclusion, it is imperative for practitioners to heighten awareness regarding the estrogen-like effects of mitotane, particularly in prepubertal childhood. Precocious puberty, while treatable, may become irreversible if not recognized in a timely manner, leading to corresponding bone acceleration, early epiphyseal closure, and short stature. This is particularly significant given the increasing “off-label” use of mitotane for pediatric adrenocortical carcinomas, despite the absence of definitive evidence supporting its benefits. The pediatric endocrine/oncology community should proactively undertake investigations to thoroughly assess the efficacy and toxicity profile of mitotane in the pediatric population. Such efforts are crucial for establishing evidence-based guidelines and ensuring the safe and effective use of mitotane in pACC.

Ethical clearance

Not required.

Funding

None.

Patient's/Guardian's consent

Guardian's full consent is given.

Declaration of competing interest

None.

Declaration of generative AI and AI-assisted technologies in the writing process

During the preparation of this work the author(s) used ChatGPT 3.5 in order to modify the language. After using this tool/service, the author(s) reviewed and edited the content as needed and take(s) full responsibility for the content of the publication.

References

- [1] Riedmeier M, Decarolis B, Haubitz I, Müller S, Uttinger K, Börner K, et al. Adrenocortical carcinoma in childhood: a systematic review. *Cancers* 2021;13(21).
- [2] Wasserman JD, Novokmet A, Eichler-Jonsson C, Ribeiro RC, Rodriguez-Galindo C, Zambetti GP, et al. Prevalence and functional consequence of TP53 mutations in pediatric adrenocortical carcinoma: a children's oncology group study. *J Clin Oncol* 2015;33(6):602–9.
- [3] Wagner J, Portwine C, Rabin K, Leclerc JM, Narod SA, Malkin D. High frequency of germline p53 mutations in childhood adrenocortical cancer. *J Natl Cancer Inst* 1994;86(22):1707–10.
- [4] Kleihues P, Schäuble B, zur Hausen A, Estève J, Ohgaki H. Tumors associated with p53 germline mutations: a synopsis of 91 families. *Am J Pathol* 1997;150(1):1–13.
- [5] Uttinger KL, Riedmeier M, Reibetanz J, Meyer T, Germer CT, Fassnacht M, et al. Adrenalectomies in children and adolescents in Germany - a diagnose related groups based analysis from 2009-2017. *Front Endocrinol* 2022;13:914449.
- [6] Rodriguez-Galindo C, Krailo MD, Pinto EM, Pashankar F, Weldon CB, Huang L, et al. Treatment of pediatric adrenocortical carcinoma with surgery, retroperitoneal lymph node dissection, and chemotherapy: the children's oncology group ARAR0332 protocol. *J Clin Oncol* 2021;JCO2002871.
- [7] Veytsman I, Nieman L, Fojo T. Management of endocrine manifestations and the use of mitotane as a chemotherapeutic agent for adrenocortical carcinoma. *J Clin Oncol* 2009;27(27):4619–29.
- [8] Rossini E, Giacomuzzi E, Gangemi F, Tamburello M, Cosentini D, Abate A, et al. Estrogen-like effect of mitotane explained by its agonist activity on estrogen receptor- α . *Biomedicines* 2021;9(6).
- [9] Fassnacht M, Dekkers OM, Else T, Baudin E, Berruti A, de Krijger R, et al. European society of endocrinology clinical practice guidelines on the management of adrenocortical carcinoma in adults, in collaboration with the European network for the study of adrenal tumors. *Eur J Endocrinol* 2018;179(4):G1–46.
- [10] Oddie PD, Albert BB, Hofman PL, Jefferies C, Laughton S, Carter PJ. Mitotane in the treatment of childhood adrenocortical carcinoma: a potent endocrine disruptor. *Endocrinol Diabetes Metab Case Rep* 2018;2018.
- [11] Steenaard RV, Rutjens M, Ettaieb MHT, van Noessel MM, Haak HR. EDP-mitotane in children: reassuring evidence of reversible side-effects and neurotoxicity. *Discov Oncol* 2022;13(1):25.
- [12] Wieneke JA, Thompson LD, Heffess CS. Adrenal cortical neoplasms in the pediatric population: a clinicopathologic and immunophenotypic analysis of 83 patients. *Am J Surg Pathol* 2003;27(7):867–81.
- [13] Redlich A, Boxberger N, Strugala D, Frühwald MC, Leuschner I, Kropf S, et al. Systemic treatment of adrenocortical carcinoma in children: data from the German GPOH-MET 97 trial. *Klin Pädiatr* 2012;224(6):366–71.
- [14] Virgone C, Roganovic J, Vorwerk P, Redlich A, Schneider DT, Janic D, et al. Adrenocortical tumours in children and adolescents: the EXPERT/PARTNER diagnostic and therapeutic recommendations. *Pediatr Blood Cancer* 2021;68(Suppl 4):e29025.
- [15] Kuhlen M, Mier P, Kunstreich M, Lessel L, Schneider D, Brecht I, et al. Key factors for effective mitotane therapy in children with adrenocortical carcinoma. *Endocr Relat Cancer* 2022;29(9):545–55.
- [16] Fassnacht M, Assie G, Baudin E, Eisenhofer G, de la Fouchardiere C, Haak HR, et al. Adrenocortical carcinomas and malignant pheochromocytomas: ESMO-EURACAN Clinical Practice Guidelines for diagnosis, treatment and follow-up. *Ann Oncol* 2020;31(11):1476–90.
- [17] Terzolo M, Fassnacht M. Endocrine tumours: our experience with the management of patients with non-metastatic adrenocortical carcinoma. *Eur J Endocrinol* 2022;187(3):R27–40.
- [18] Basile V, Puglisi S, Calabrese A, Pia A, Perotti P, Berruti A, et al. Unwanted hormonal and metabolic effects of postoperative adjuvant mitotane treatment for adrenocortical cancer. *Cancers* 2020;12(9).
- [19] Reimondo G, Puglisi S, Zaggia B, Basile V, Saba L, Perotti P, et al. Effects of mitotane on the hypothalamic-pituitary-adrenal axis in patients with adrenocortical carcinoma. *Eur J Endocrinol* 2017;177(4):361–7.
- [20] Daffara F, De Francia S, Reimondo G, Zaggia B, Aroasio E, Porpiglia F, et al. Prospective evaluation of mitotane toxicity in adrenocortical cancer patients treated adjuvantly. *Endocr Relat Cancer* 2008;15(4):1043–53.